

# 20-Month-Old Calcinosis Cutis Healed in 33 Vaporox Treatments

## Case Study

### Wound Healing Journey

Tracy D. began his battle with severe Calcinosis Cutis (CC) in May 2023, developing extensive wounds around the gaiter area of both legs. His healing was complicated by multiple comorbidities, including Chronic Myelogenous Leukemia, COPD, venous hypertension, and diabetes.

Initial treatments with Santyl and oral steroids failed to improve the wounds, and his condition worsened until the leukemia medication Tasigna was discontinued. In October 2023, Tracy started Vaporox therapy and began to show progress. However, insurance denied continued coverage, forcing a pause in treatment. After transitioning to Medicare, he resumed Vaporox in April 2024, leading to significant wound closure. Despite compliance issues and recurrent infections, he still responded to therapy and was sufficiently healed by January 2025 to be discharged to standard care.

#### Patient Information

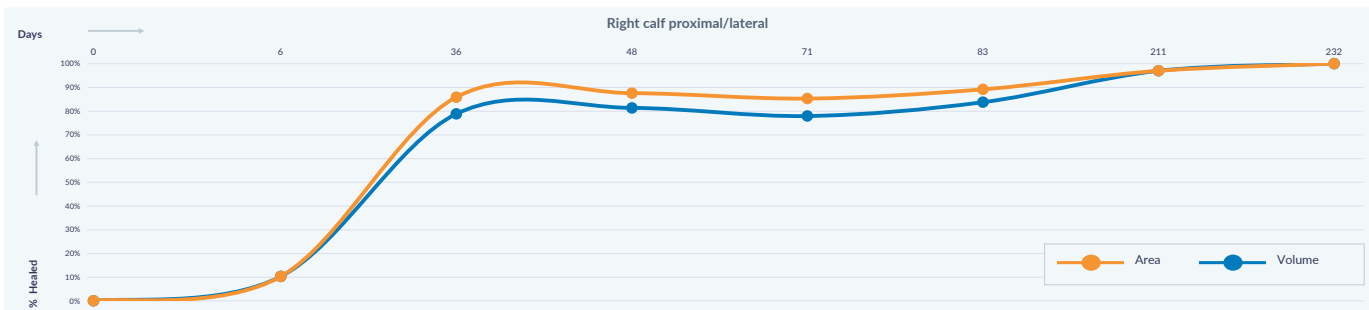
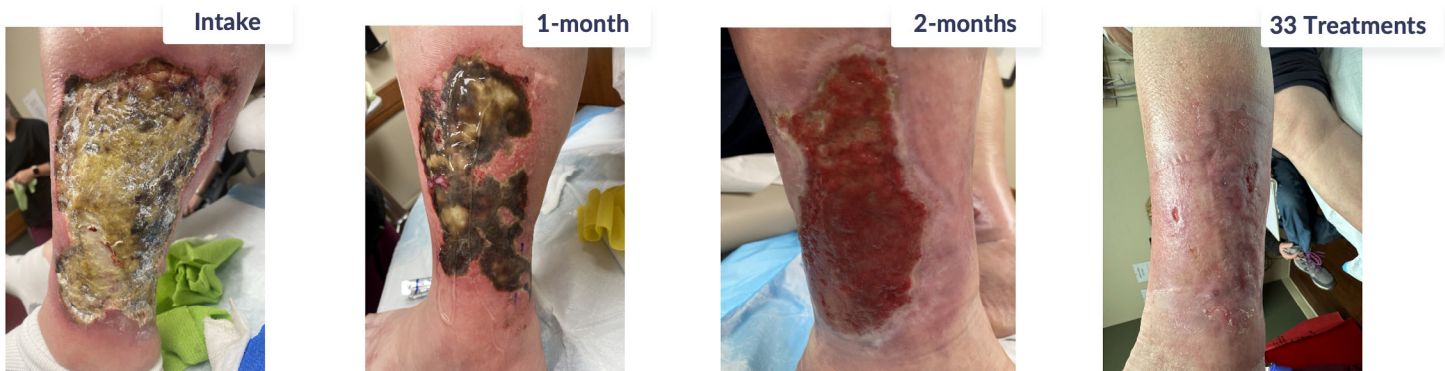- Age: 61
- Gender: Male
- Initial Diagnosis: Calcinosis Cutis
- Initial Evaluation: May 2023

#### Previous Treatments:

- SWC
- Allograft grafting
- Steroids
- 10 months of debridement in OR
- Compression
- Santyl

#### Comorbidities:

- CAD/COPD
- Venous Hypertension
- Chronic Myelogenous Leukemia
- Sleep Apnea
- Type 2 - Diabetes



> "We were not able to heal this difficult wound until we started using Vaporox."



- Michael Duehrrsen, MD.

Vaporox